

Uterine Arteriovenous Malformation

Khadija Ranjha¹, Nurunnisa Nabil², Komal Naz Khalid³, Atif Rana⁴, Nabia Tariq⁵

¹⁻³M.B.B.S Medical students, Shifa College of Medicine, Islamabad, ⁴Consultant Radiologist, Shifa Int. Hospital, Islamabad, ⁵ Professor Obs/gynae, Shifa Int. Hospital, Islamabad.

Correspondence: prof. Nabia Tariq, Professor of Obs/Gynae, Shifa Int. Hospital, Islamabad.

Email: nabiatariq_fcps@yahoo.com

Abstract

Uterine arteriovenous malformations (UAVM) are a rare phenomenon, with very few reported cases. Our patient presented with vaginal bleeding after Dilatation & Curettage performed for incomplete miscarriage. MRI revealed an heterogenous exophytic, highly vascularized area in the anterior myometrial cavity. Uterine arteriovenous malformation (UAVM) was confirmed on angiography. The patient underwent uterine artery embolization (UAE) for her curative treatment.

Keywords: uterine arteriovenous malformations, Vaginal bleeding, Uterine artery embolization.

Introduction

Uterine arteriovenous malformations are a rare disorder with less than 100 reported cases.¹ It is characterized by aberrant channels that form between the arteries and veins, and can be congenital or acquired after endo-uterine trauma.²

UAVMs typically present as heavy vaginal bleeding, and are associated with spontaneous abortions, multiple pregnancies, and previous history of dilation and curettage, therapeutic abortion or LSCS. Diagnosis can be made on ultrasound of pelvis and MRI, but angiography is the gold standard.

Case Report

A patient, 38 year old South Asian woman, with no known co-morbid, married for four years, P₁⁺², last child born was a female two and a half years ago via a lower segment CS due to deficient progress of labour, now the child alive and healthy presented to

Shifa Int. Hospital . She had two miscarriages within the past nine months. The first miscarriage was nine months ago followed by D&C, she started experiencing vaginal bleed after the procedure which alternated between heavy bleeding and spotting. It was associated with passage of clots, there was no dysmenorrhea or fever. An MRI was done which showed an heterogeneous exophytic, highly vascularized area in the anterior myometrial cavity. A differential of arteriovenous malformation or cystic degeneration of uterine fibroids was made. She was managed meanwhile on norethisterone and tranexamic acid, but had little improvement in her symptoms.

She had her second miscarriage five months ago, which was managed medically with PGE1 vaginal tablet, and an ultrasound pelvis was carried out which showed a mass lesion in the uterus with prominent vascular channels, with mixed arterial and

venous pattern of blood flow, draining into the pelvic vasculature. She was suspected to have UAVM which was later on confirmed on angiography. The angiography showed presence of arteriovenous malformation along the anterior uterine wall with thrombus formation, which made the visualization of the malformation itself difficult. UAE was carried out preemptively for possible reopening of the malformation via collaterals.

The patient has shown marked improvement in symptoms since the embolization. Figures 1-5 show the imaging appearances of the patient.

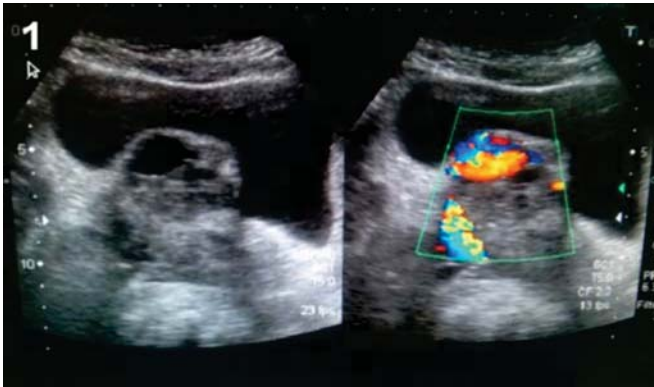

Figure 1. Pelvic USG showing empty cystic spaces with enhanced blood flow on color doppler.

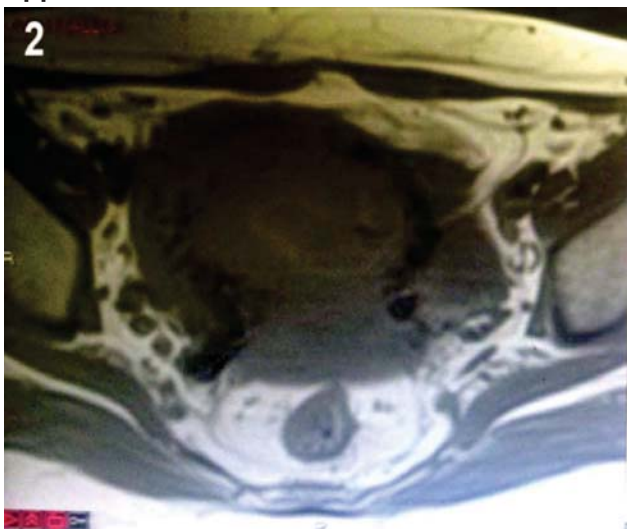


Figure 2. Multiple flow voids in T1 MRI.

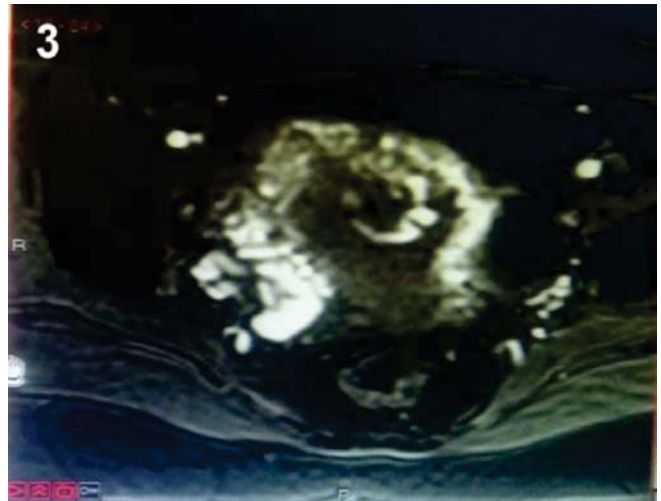


Figure 3. T2 MRI showing dynamic contrast enhancement consistent with vascular malformations.

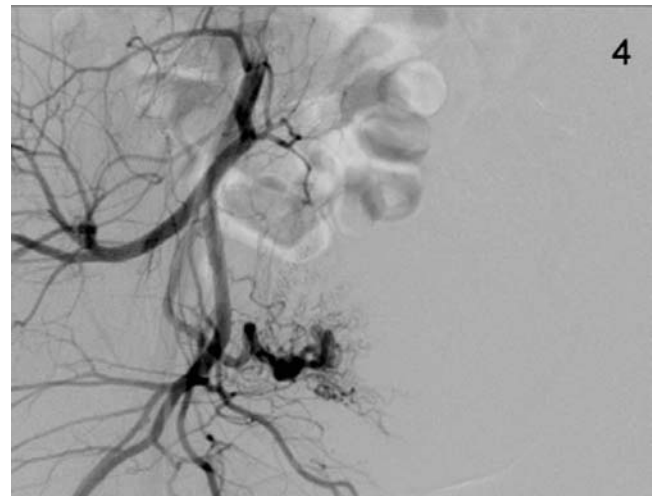


Figure 4. Uterine artery angiography showing slow flow in spiral arteries (Pre embolization).

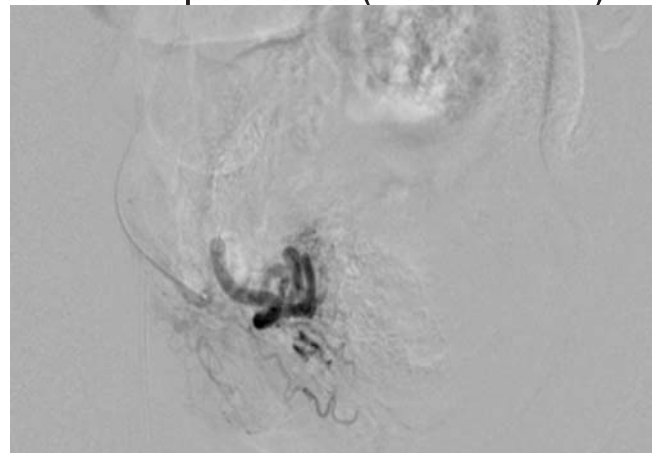


Figure 5. Uterine artery angiography (Post embolization).

Discussion

Vascular abnormalities are very rare in gynaecology. However, UAVM is potentially life threatening and patients present with vaginal bleeding that may be profuse and cause hemodynamic instability. Thus, it is an important differential diagnosis to be considered in women of reproductive age with unexplained vaginal bleeding and in post-menopausal women when anechoic structures are identified by ultrasonography.³ Dubreil et al⁴ first described them in 1926 as cirroid aneurysms since then they have been referred to as arteriovenous aneurysms or arteriovenous malformations. Less than hundred cases of AVM have been reported in the literature.⁵ AVM is diagnosed in a woman of reproductive age with complaints of vaginal bleeding and a negative Beta HCG test. USG, Doppler and MR-angiography are the investigations used for the diagnosis of AVM, with angiography being the gold standard. Three-dimensional computed tomography (CT) angiography can determine the actual extent of the vascular malformation and helps in pre-interventional planning noninvasively.⁶ Differential diagnoses of AVM include true aneurysm, pseudoaneurysm and chorangioma of the placenta.

Similar case of AVM have been reported by Hashim et al¹, in which a patient presented with two episodes of heavy vaginal bleeding. On angiography of the uterine artery, an arteriovenous malformation in the fundal region and multiple feeding arteries were seen. Embolization of both uterine arteries was performed, which decreased the vaginal bleeding significantly post embolization. Another case reported by Alessandrino et al,⁷ was of a 39 year old

lady with complaints of a uterine mass, metrorrhagia and drop in haemoglobin level. MR-angiography of the patient showed UAVM and UAE were performed successfully. Ayyaipan et al⁶ described two cases which developed arteriovenous malformations after dilation & curettage, thus showing an iatrogenic link similar to our patient. The treatment of choice is now UAE because of its high success rate and minimum complications, although hysterectomy may be an option if the bleeding is profuse.⁸

Whether this procedure is safe for women desiring future fertility is controversial however women who become pregnant after UAE are at risk for malpresentation, preterm birth, caesarean delivery, and postpartum hemorrhage.⁹

Conclusion

UAVM is often suspected by Doppler ultrasound while Angiography confirms the diagnosis. UAE seems to be currently the best treatment.

References

1. Hashim H, Nowawi O. Uterine Arteriovenous Malformation. *Malays J Med Sci*.2013;20(2):76-80.
2. Sanguin S, Lanta-Delmas S, Le Blanche A, et al. Uterine arteriovenous malformations: diagnosis and treatment in 2011. *Gynecol Obstet Fertil* 2011 Dec;39(12):722-727.
3. Polat P, Suma S, Kantarcy M, Alper F, Levent A. Colour Doppler Ultrasound in the Evaluation of Uterine Vascular Abnormalities. *Radiographics* 2002;22:47-53.
4. Dubreuil, G. and Loubat, E. Aneurisme cirroid de l'uterus. *Ann. Anat. Pathol* 1926; 3: 697-718.
5. Hickey M, Fraser I. Clinical Implications of Disturbances of Uterine Vascular Morphology and Function. *Baillieres Clin Obstet Gynaecol* 2000; 14(6):937-951.
6. Aiyappan SK, Ranga U, Veeraiyan S. Doppler Sonography and 3D CT Angiography of Acquired

- Uterine Arteriovenous Malformations: Report of Two Cases. J Clin Diagn Res 2014;8(2):187-189.
7. F. Alessandrino, E. Di Silverio, L. P. Moramarco. Uterine Arteriovenous Malformation. J Ultrasound 2013;16(2):41-44.
 8. Singh N, Tripathi R, Mala YM, Tyagi S, Tyagi S, Singh C. Varied presentation of uterine arteriovenous malformations and their management by uterine artery embolisation. J Obstet Gynaecol 2014;34(1):104-106.
 9. Goldberg J, Pereira L, Berghella V. Pregnancy after uterine artery embolization. Obstet Gynecol 2002. Nov;100(5 Pt 1):869-872.

Updated instructions towards the end of each issue of JSOGP must be read carefully by all authors, before submission of their manuscripts.

Editor-in-Chief